

Chemical Composition, Total Phenolic Content, and Anti-Ulcerative Colitis Effects of Extract and Essential Oil of *Cupressus arizonica* Greene Fruits

Mohammad Bagher Majnooni^{1,2}, Saeid Mohammadi², Gholamreza Bahrami¹,
Ehsan Mohammadi-Noori¹, Mohammad Hosein Farzaei^{1*}

¹Pharmaceutical Sciences Research Center, Health Institute, Kermanshah University of Medical Sciences, Kermanshah, Iran

²Student Research Committee, Kermanshah University of Medical Sciences, Kermanshah, Iran

Received: 9 Jan 2022

Revised: 9 Mar 2022

Accepted: 11 Mar 2022

Abstract

Ulcerative colitis (UC) is a chronic inflammatory bowel disease, which has a global prevalence. Also, the plants of the Cupressaceae family have prominent anti-inflammatory and wound healing effects, so they can be considered as promising candidates for the treatment of UC. In this study, the therapeutic effects of extract and essential oil of *Cupressus arizonica* Greene (*C. arizonica*) fruits in the animal model of UC were investigated. Total of 35 Wistar male rats were treated with essential oil and hydroalcoholic extract for one week after induction of colitis by acetic acid. The colonic segment cut for macroscopic and histological analysis. The total amount of extract phenol and flavonoid content was assayed by Folin-Ciocalteu and aluminum chloride colorimetric method, respectively. The essential oil was analyzed by gas chromatography/mass spectrometer (GC/MS). The extract at doses of 100 mg/kg and 250 mg/kg and essential oil at doses of 0.5 mg/kg showed significant effects on UC ($P < 0.05$). The total phenolic content of hydroalcoholic extract in terms of mg of gallic acid/g of extract was 191.625 ± 7.04 and the amount of total flavonoids in terms of mg of rutin/g of extract was 66.52 ± 6.51 . Also, according to the results of GC/MS analysis, α -pinene was the major constituent of essential oil. Our results revealed that the extract and essential oil of *C. arizonica* fruits had therapeutic effects on UC, and this effect may be related to the presence of polyphenolic and terpene compounds.

Keywords: Ulcerative colitis; Phenolic compounds; Flavonoids; Terpenes; Essential oil; Hydroalcoholic extract; α -Pinene

Introduction

Inflammatory bowel diseases, including Crohn's disease and ulcerative colitis (UC), are among the most important gastrointestinal diseases that occur chronically and progressively [1]. UC is an inflammatory change in the mucous membranes of the large intestine that can be associated with extensive lesions from

the rectum to the beginning of the colon. UC patients suffer from clinical symptoms including cramps, diarrhea, abdominal pain, and fever. These patients are also prone to a variety of complications including reduced growth, joint and skin lesions, anemia, and different types of malignancy. Therefore, introducing a suitable treatment protocol for UC patients is pivotal

Citation: Majnooni MB, Mohammadi S, Bahrami G, Mohammadi-Noori E, Farzaei MH. **Chemical Composition, Total Phenolic Content, and Anti-Ulcerative Colitis Effects of Extract and Essential Oil of *Cupressus arizonica* Greene Fruits.** Trad Integr Med 2022;7(3):310-318.

*Corresponding Author: Mohammad Hosein Farzaei

Pharmaceutical Sciences Research Center, Health Institute, Kermanshah University of Medical Sciences, Kermanshah, Iran

E-mail: mh.farzaei@gmail.com

Copyright © 2022 Tehran University of Medical Sciences. Published by Tehran University of Medical Sciences. This work is licensed under a Creative Commons Attribution-NonCommercial 4.0 International license (<https://creativecommons.org/licenses/by-nc/4.0/>). Noncommercial uses of the work are permitted, provided the original work is properly cited.



[2]. Nowadays, pharmacotherapy and surgery are two main strategies of UC treatment. However, surgical treatment is recommended only in cases of severe inflammation, rupture of the colon, refractory bleeding to treatment, and megacolon toxicum [3,4]. On the other hand, anti-inflammatory and immunomodulatory drugs including sulfasalazine, olsalazine, mesalazine, azathioprine, 6-mercaptopurine, methotrexate, cyclosporine, and infliximab are the main UC treatments [4-8]. However, no definitive treatment has been provided for this disease so far, and common medicines have numerous side effects, as well as high costs. So, research to discover effective drugs seems reasonable and necessary [9]. On the other hand, medicinal plants and natural products, with simultaneous effects on multiple therapeutic targets, fewer side effects, and easy accessibility, are always one of the promising candidates for treating diseases with complex pathogenesis, such as UC [10]. *Cupressus arizonica* Greene (Cupressaceae) is an evergreen coniferous tree with needle leaves and native to the southwestern United States of America, which has been imported to Iran since 1954 and has spread throughout the country. Antifungal, antibacterial, antioxidant, and larvicidal properties were reported as major biological activities of *C. arizonica* [11-14]. Also, the different species of *Cupressus* genus showed analgesic, anti-inflammatory [15], antioxidant [16], cytotoxicity [17-19], and antimicrobial effects [20]. Besides, studies showed that the *C. sempervirens* extract improved gastric ulcer healing and UC via increasing antioxidant capacity in rats [21,22]. Based on the chemical composition analysis, α -pinene is the main compound of *Cupressus* spp. essential oil [23]. Several studies show the protective and therapeutic effect of α -pinene in the UC and gastrointestinal ulcers [24-26]. Also, polyphenolic compounds in *Cupressus* plants revealed notable anti-UC and anti-inflammatory effects [27,28]. Accordingly, the aim of this study is to evaluate the chemical composition and preliminary phytochemical screening of the essential oil and hydroalcoholic extract prepared from *C. arizonica* fruits and to investigate their therapeutic effects in the animal model of UC.

Materials and Methods

Plant material

The fruits of *C. arizonica* were collected in April 2020 from the Garden of Kermanshah School of Pharmacy and the voucher specimen was deposited with voucher number 085-003-001 at the herbarium of the Pharmacognosy Department, School of Pharmacy, Kermanshah University of Medical Sciences, Kermanshah, Iran.

Isolation of the essential oil

The fruits of *C. arizonica* were dried in the shade

and the outer shell was crushed. The essential oil was obtained by hydrodistillation method for 4 h using a Clevenger-type apparatus. Anhydrous sodium sulfate was used to adsorb water residue. The oil was then stored at -20 °C until further analysis. Results of the GC/MS analysis of essential oil has already been reported in another study by our team [29].

Preparation of extract

The powdered fruits (200 g) were extracted with 800 mL of ethanol 70% on the shaker for 72 h at room temperature and then it was filtered with a Buchner funnel and Whatman No.1 filter paper. The extract was concentrated using a rotary evaporator at reduced pressure at a temperature below 45 °C and residuals dried at room temperature. The dried extract was stored at -20 °C until further evaluations.

Preliminary phytochemical screening

Phytochemical screening was conducted using standard methods to detect the plant secondary metabolites, including alkaloids, tannins, saponins, terpenoids, steroids, anthraquinones, coumarins, flavonoids, and phenolic compounds [30].

Determination of total phenolic contents

The total amount of phenol in the hydroalcoholic extract of *C. arizonica* fruits was evaluated by Folin-Ciocalteu colorimetric method. Concentration of 1 mg/mL of the extract was prepared in methanol and then 0.5 mL of the extract was mixed with 2.5 mL of 10% Folin-Ciocalteu reagent and was shaken for 5 min. Then 2 mL of sodium carbonate solution (75 g/L) was added. The absorbance of the samples was measured after 2 hours by an ultraviolet spectrophotometer at a wavelength of 760 nm versus the blank. Finally, the total phenolic content of the extract was measured using a standard curve based on mg of gallic acid per g of extract [31].

Determination of total flavonoid content

Total flavonoid concentration was measured by aluminum chloride colorimetric method. The amount of 0.5 mL of the extract solution was mixed with 1.5 mL of ethanol 95 %, 0.1 mL aluminum chloride 10%, and 0.1 mL of potassium acetate 1 M and 2.8 mL of distilled water. After storing the samples for 30 min at room temperature, the absorbance of the resulting mixture was measured at 415 nm. The total flavonoid content considering the standard calibration curve of rutin, was expressed as mg of rutin equivalent per g of extract [32-34].

Animals

Thirty-five male Wistar rats, in weight range 180-220 g, were purchased from the animal center of

Kermanshah School of Pharmacy, Iran. All rats were maintained in standard laboratory conditions of temperature (23 ± 2 °C), relative humidity (55%), light: dark cycle (12:12 h), food, and water. All experiments in this study were performed in accordance with the ethical standards of the Helsinki Declaration of 2008 and were approved by the Ethics Committee for the Care and Use of Laboratory Animals of Kermanshah University of Medical Sciences (IR.KUMS.REC.1398.866).

Experimental design

To evaluate the therapeutic effects of *C. arizonica* fruits, male Wistar rats received the essential oil and hydroalcoholic extract for one week after induction of colitis. The extract was administered orally (p.o.) at doses of 100, 250, and 500 mg/kg, and the essential oil was administered intra-rectally (i.r.) at doses of 0.5 and 1 g/kg. Thirty-five rats were divided into seven groups (5 rats each) as follow:

- Group A: Positive control (received mesalazine at a dose of 500 mg/kg p.o./ i.r.)
- Group B: Negative control (received 1ml of normal saline p.o. and/or i.r.)
- Group C: receiving fruit extract (100 mg/kg, p.o.)
- Group D: receiving fruit extract (250 mg/kg, p.o.)
- Group E: receiving fruit extract (500 mg/kg, p.o.)
- Group F: receiving fruit essential oil (0.5 mg/kg, i.r.)
- Group G: receiving fruit essential oil (1 mg/kg, i.r.)

Induction of colitis

For the induction of colitis, the animals were fasting for 24 h. The rats were anesthetized by intraperitoneal injection of ketamine (100 mg/kg), and then 1 mL of 4% acetic acid was administered the rats were maintenance supine in the trendelenburg position for 30 seconds to prevent early leakage.

Evaluation of colon macroscopic damage

On the eighth day after induction of colitis, all animals were euthanized by ether overdose inhalation. The 8 cm of the distal colon was isolated and cleaned up by normal saline. Macroscopic mucosal damage was assessed according to Gerald's scoring system (Table 1) and based on wound size, the severity of inflammation, and hyperemia [35].

Evaluation of colon microscopic damage

For microscopic evaluation, the removed colon segments (2 cm) were fixed in formalin 10% and were cut into 5 μ m thickness sections after embedding in paraffin. These slides were stained with hematoxylin and eosin for suitable studying under the light microscope and scoring was performed by a blinded pathologist. The microscopic scoring criteria were shown in table 1.

Table 1. The microscopic scoring criteria according to Gerald's system

Score for macroscopic damage	Score for microscopic damage
0 No ulcer, No inflammation	0 No damage
1 No ulcer, local hyperemia	1 Focal epithelial edema and necrosis
2 Ulceration without hyperemia	2 Disperse swelling and necrosis of the villi
3 Ulceration and inflammation at one site only	3 Necrosis with neutrophil infiltration in submucosa
4 Ulceration extending more than 2 cm	4 Wide spread necrosis with massive neutrophil infiltration and hemorrhage
5 Two or more sites of ulceration and inflammation	

Statistical analysis

One-way ANOVA with Tukey post hoc test was used to analyze the data. Data were shown as mean \pm SD. $P < 0.05$ was considered as a significant level.

Results

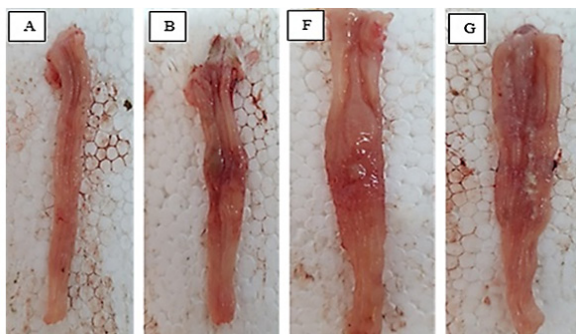
Preliminary phytochemical screening

The results of the qualitative phytochemical analysis were shown in table 2. The results showed the presence of saponins, terpenoids, tannins, alkaloids, and coumarins in the hydroalcoholic extract of *C. arizonica* fruits. Also, the amount of total phenol of extract was measured by the Folin-Ciocalteu method according to the gallic acid (mg) standard curve equation. The total phenolic content of the hydroalcoholic extract of *C. arizonica* fruit was calculated at 191.625 mg gallic acid equivalent/ g of extract powder. Besides, the total amount of flavonoid content in *C. arizonica* fruit extract was measured by the aluminum chloride colorimetric method. The amount of flavonoid obtained was calculated after placing the amount of fruit extract absorption in the equation of the rutin standard curve. The obtained results showed that the amount of flavonoid was calculated at 66.52 mg of rutin per gram of extract. To our knowledge, this is the first report to determine the total phenolic and flavonoid content of *C. arizonica* fruit. On the other hand, the results of GC/MS analysis for *C. arizonica* fruits essential oil showed that α -pinene (71.92%) was the major essential oil constituent. Other GC/MS analysis data were reported in a parallel project performed by the authors

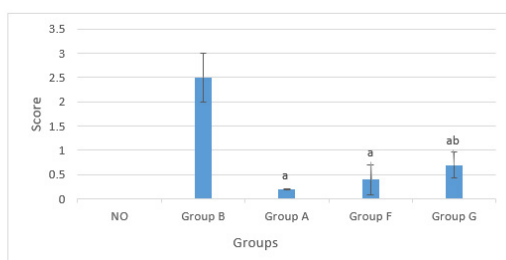
of the present article [29].

Macroscopic assessment of colonic damage

For macroscopic examination of rat colon, the Gerald method was used to score different groups based on the severity of inflammation, mucosal wound size, and hyperemia. In groups, receiving *C. arizonica* extract in three doses of 100, 250, and 500 mg/kg, reducing inflammation and wound healing in rats with colitis was observed. Our results showed that the lowest inflammation and the highest wound healing in rats with colitis belonged to the group receiving 100 mg/kg of *C. arizonica* fruit extract (group C), which had a significant difference from the negative control treatment (Figure 2A and 2B). Besides, the lowest rate of inflammation and the highest wound healing in rats receiving essential oil belonged to the group taking the dose of 0.5 mg/kg (group F), which had a statistically significant difference with the negative control treatment (Figure 1.A and 1B). On other hand, the C and F groups had no significant difference with mesalazine. Moreover, the treatments in all doses had no significant effects on the weight of rats.



1A)



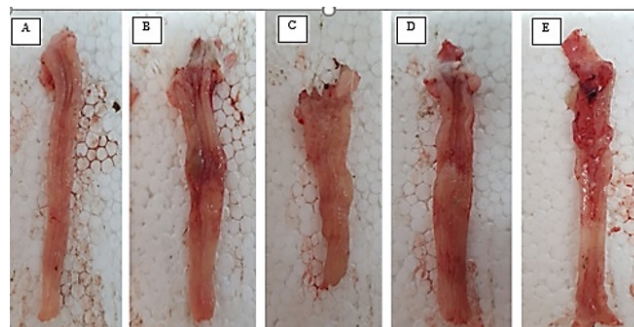
1B)

Figure 1A. Macroscopic appearance of rat colon treated with acetic acid as negative control group (B), mesalazine (A) and *C. arizonica* fruit essential oil at 0.5 mg/Kg (F) and 1 mg/Kg (G). **1B.** The efficacy of the essential oil treatment on rat colon injuries induced with acetic acid based on the scored described in table 1. The efficacy of the treatment with essential oil at 0.5 mg/Kg (F) and mesalazine (A) in reducing the mucosal damage compared with negative control group (a: $p < 0.05$). The efficacy of the essential oil at 100 mg/Kg (G) had significantly less effect than mesalazine in healing damaged colon (b: $p < 0.05$).

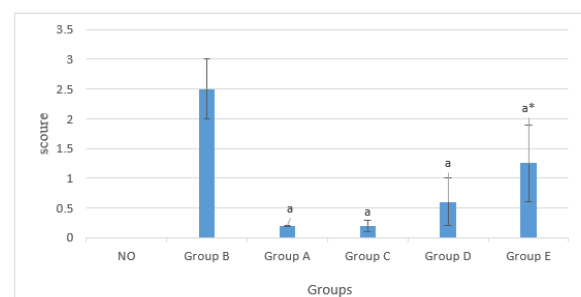
Table 2. phytochemical analysis screening of *C. arizonica* extract

Secondary metabolite	Extract content
Alkaloids	+
Anthraquinones	-
Saponins	+++
Terpenoids	+++
Tannins	++
Coumarins	+
Steroids	+
Total Phenol Content mg gallic acid /g extract*	191.625 ± 7.04
Total Flavonoid Content mg Rutin /g extract*	66.52 ± 6.51

*Experiment was performed in triplicate and expressed as mean ±SD



2B)



2A)

Figure 2A. Macroscopic appearance of rat colon treated with acetic acid as negative control group (B), mesalazine (A) and *C. arizonica* fruit extract at 100 mg/Kg (C) and 250 mg/Kg (D). **2B.** Macroscopic injuries of rat colon induced with acetic acid was scored as described in Table 1. All studies groups have significant effect on reducing the mucosal injuries ($p < 0.05$) compared with negative control group (a). The extract at 500 mg/Kg (D) is shown a significant difference ($p < 0.05$) with mesalazine (*) and had less effect than other groups in healing damaged colons.

Table 3. Histopathological analysis of the colon in different groups

No	Colon Changes	NO	A	B	C	D	E	F	G
1	Structure	-	++	+++++	+++	+++	++++	+++	++++
2	Necrosis	-	+	+++++	++	++	++++	++	++++
3	Inflammation	-	++	+++++	++	+++	++++	+	++++

A: Positive control (mesalazine, 500 mg/kg), B: Negative control (Normal saline), C: fruit extract (100 mg/kg), D: fruit extract (250 mg/kg), E: fruit extract (500 mg/kg), F: fruit essential oil (0.5 mg/kg), G: fruit essential oil (1 mg/kg)

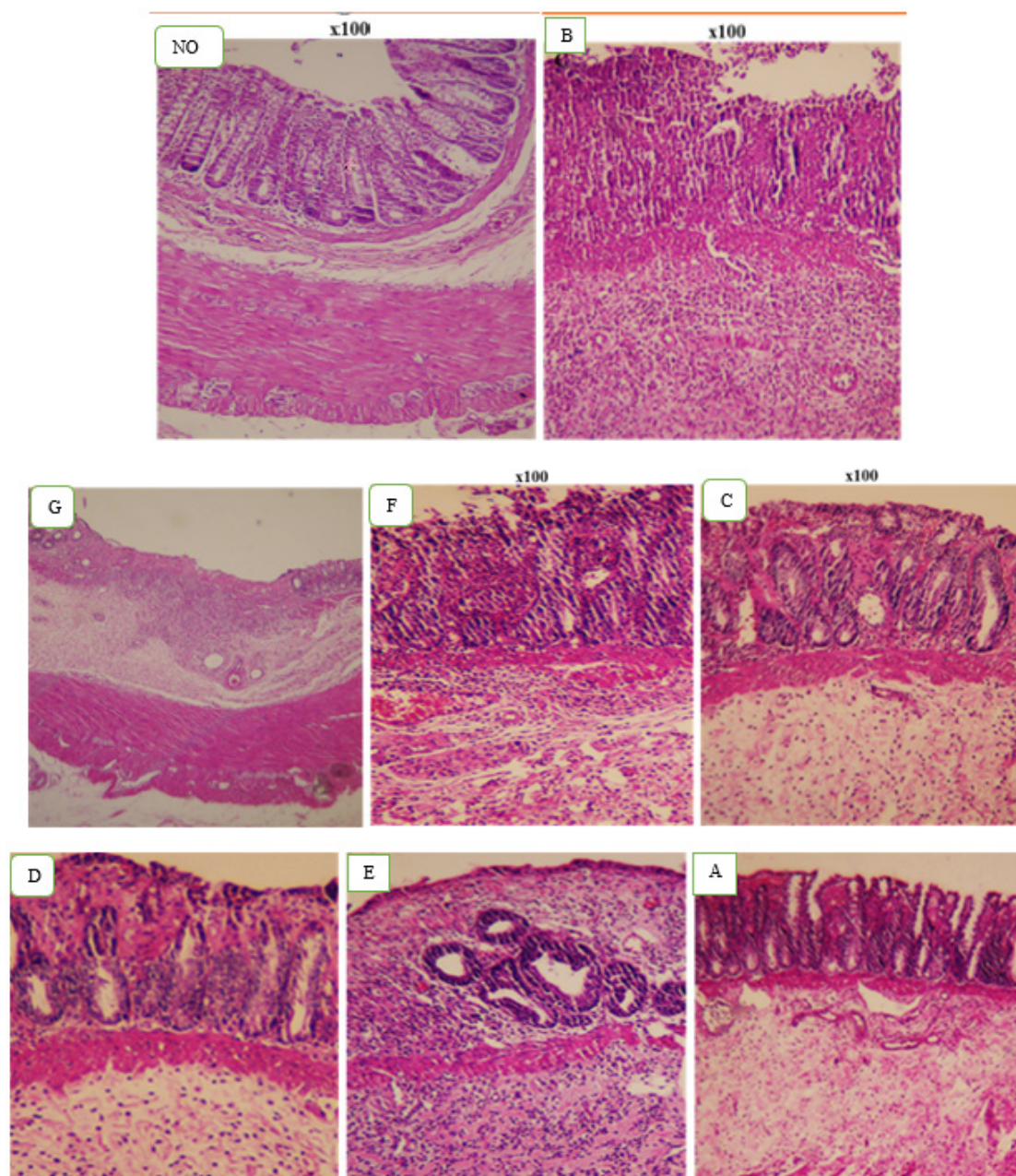


Figure 3. Histological sections of colonic tissue stained with hematoxylin and eosin. Normal group and mucosal layer (NO), negative control group acetic acid induced colitis rat with mucosal injury and extensive damage as well as severe inflammatory cell infiltration (B). In the groups receiving the extract with doses of 100 mg/Kg (C), 250 mg/Kg (D), and mesalazine (A), as well as essential oil at 0.5 mg/Kg (F) the injuries effects of colitis were significantly reduced and most parts of intestinal tissue were detectable. Intestinal tissue changes were observed in the group receiving extract at 500 mg/Kg (E) as in the group receiving essential oil at 1 mg/Kg (G).

Microscopic assessment of colonic damage

The results from microscopic studies performed as histological studies by hematoxylin-eosin showed that intestinal tissue is injured in the negative control group and the different parts are indistinguishable, and accumulation of inflammatory cells are seen in the mucosa and under the mucosa (Figure 3). In the group receiving essential oil at a dose of 1 mg/kg, as in the negative control group, there were changes in intestinal tissue. In the group receiving essential oil at 0.5 mg/kg, tissue damage was markedly improved. In the C, D, and mesalazine groups the destructive effects of colitis were dramatically reduced, and most parts of intestinal tissue were detectable. In the group receiving a dose of 500 mg/kg extract the intestinal tissue changes were observed (Table 3).

Discussion

In patients with UC, inflammation causes morphological changes and ulcers in the colon, and the resulting lesions can involve the rectum to the beginning of the colon [33]. The discovery of new drugs for the treatment of UC and the identification of various mechanisms involved in this disease can be facilitated by animal modeling. Today, 4% acetic acid injected i.r. is commonly used as an animal model to evaluate the therapeutic and protective effects of various UC therapies [34]. On the other hand, herbs have always been considered by researchers as a potential, complementary and alternative treatment for UC. [9,35]. Therefore, various native and non-native plants such as *Tragopogon graminifolius* DC. [36], *Cucumis sativus* L. [37], *Hibiscus rosa-sinensis* L. [38], *Zingiber officinale* Roscoe [39] have been studied to their effectiveness in the treatment of UC. Dundar and co-workers showed that *Origanum onites* L. (Lamiaceae) essential oil ameliorated the 2,4,6-trinitrobenzenesulfonic (TBS)-induced UC through reducing the gene expression of intercellular adhesion molecule-1 and myeloperoxidase (MPO) as two critical mediators of inflammation and oxidative stress [40]. Also, the essential oil of *Bunium persicum* seeds (Apiaceae) and *Foeniculum vulgare* fruits (Apiaceae) reduced the acetic acid-induced UC in rats at 200 and 400 mg/kg via inhibiting the expression of nuclear factor- κ B as one of the most main inflammation signaling pathways [41,42]. Besides, the decoction extract of *Salvia officinalis* L. leaves (Lamiaceae) showed prominent anti-UC activities in rats. This study showed that the serum antioxidant capacity significantly increased after oral administration of the decoction extract at 50, 100, and 200 mg/Kg in rats with acetic acid-induced UC [43]. Also, ethanolic extract of *Zingiber officinale* (Zingiberaceae) showed strong activities against the UC induced by acetic acid in rat through inhibiting the inflammation and antioxidant pathways [44]. Hence,

in the present study, the anti-colitis activities of *C. arizonica* fruits extract and essential oil were investigated. According to Gerald scoring, in the groups receiving *C. arizonica* fruit extract and essential oil, a significant decrease in the inflammation rate was observed after induction UC by acetic acid. The colon histological assay showed that the rate of inflammation was severe in the negative control group. On the other hand, the rate of inflammation and accumulation of inflammatory cells in the mucosa and submucosa were decreased significantly in the groups receiving extracts and essential oils compared to the negative control group. Also, the extract at 100 mg/kg and essential oil at 0.5 mg/kg showed the best results in the studied groups. The anti-colitis therapeutic agents show their effects through several main mechanisms including the antimicrobial effects, antioxidant activities, and the inhibitory effects on gene expression of inflammation signaling pathways such as mitogen-activated protein kinase, interleukin (IL) 1,4,8, and tumor necrosis factor- α (TNF- α). Therefore, it can be concluded that the extract and essential oil of *C. arizonica* fruit may be effective in modulating or eliminating the symptoms of UC via the mentioned mechanisms [45-49]. Besides, anti-inflammatory and antioxidant effects of other species of the *Cupressus* genus including *C. sempervirens*, *C. cashmeriana*, and *C. macrocarpa* have been reported in several articles [15,17,22,28,50,51]. Sepehrimanesh and co-workers reported that the hydroalcoholic extract of *C. sempervirens* leaf has therapeutic and regenerative effects on UC induced by acetic acid. They showed that gels containing 0.5% and 1% of the extract significantly increased superoxide dismutase activities, as an antioxidant marker, in damaged colon tissue. On the other hand, they have related these beneficial effects of the *C. sempervirens* leaf extract on UC to the presence of ameno flavone, myricitrin, and quercetin as the polyphenolic compounds [22,28]. Tumen et al. also showed that *C. sempervirens* fruit essential oil in a dose of 1% has wound-healing effects in rats [51]. Besides, Su and co-workers showed that the essential oil of the leaf and twigs of *C. cashmeriana* have antimicrobial, antioxidant, and anti-inflammatory effects. In this study, α -pinene and carvacrol methyl ester were reported as the major compounds of leaf and twigs essential oils, respectively [50]. Our preliminary phytochemical results on *C. arizonica* fruit hydroalcoholic extract showed high polyphenol content alongside other phytochemicals included terpenoids, tannins, alkaloids, and coumarins (Table 2). Studies demonstrate the potential ability of polyphenolic compounds to treat UC [52]. Polyphenolic compound of *Ocimum gratissimum* L. leaves (Lamiaceae) showed significant preventive effects on Dextran sodium sulfate -induced UC in rat via reducing serum level of

TNF- α and IL-6 as pro-inflammatory cytokines [53]. Also, gallic acid, as a polyphenolic compound abundantly found in plants, inhibited MPO activities in rat colon tissues, thereby showing significant protective effects on TBS-induced UC [54]. On the other hand, preliminary phytochemical studies on *C. arizonica* fruit hydroalcoholic extract showed the presence of high amounts of saponin and terpenoid compounds (Table 2). Investigations show prominent anti-inflammatory and anti-UC effects for saponins and terpenoids [55,56]. The total saponins of *Astragalus membranaceus* (Fisch.) Bunge (Fabaceae), *Panax notoginseng* (Burkill) F.H.Chen (Araliaceae), *Pulsatilla chinensis* (Bunge) Regel (Ranunculaceae) revealed a significant therapeutic and protective effects on UC in rats [57-59]. Besides, *C. arizonica* fruit essential oil analysis showed that the α -pinene (71.92%) is the essential oil major compound. The α -pinene content of *C. arizonica* fruit essential oil was reported 57.7% in another study [60]. Several studies confirm the protective and therapeutic effect of α -pinene on inflammatory diseases such as UC [49,61]. Besides, the weight of rats at the end of the period present study was not significantly different from the positive control group, which indicates the process of healing and repairing the gastrointestinal tract and increasing its absorption function.

Conclusion

According to the microscopic and macroscopic results obtained from the present study, the damage caused by colitis induction with acetic acid was significantly reduced in the groups receiving essential oil and hydroalcoholic extract of *C. arizonica* fruit in comparison to the control group, especially in doses of 0.5 mg/kg essential oil and 100 mg/kg of the extract. So, the results of this study could pave the way for further practical investigation and clinical trial studies on *C. arizonica* fruit as a complementary medicine for the treatment UC.

Conflict of Interests

Authors declare that there is no conflict of interest.

Funding

This work was supported by Kermanshah University of Medical Sciences, Iran

Acknowledgements

None.

References

- [1] Guan Q. A comprehensive review and update on the pathogenesis of inflammatory bowel disease. *J Immunol Res* 2019;7247238.
- [2] Ishihara S, Kawashima K, Fukuba N, Tada Y, Kotani S, et al. Irritable bowel syndrome-like symptoms in ulcerative colitis patients in clinical remission: association with residual colonic inflammation. *Digestion* 2019;99:46-51.
- [3] Berends SE, Strik AS, Löwenberg M, D'Haens GR, Mathôt RA. Clinical pharmacokinetic and pharmacodynamic considerations in the treatment of ulcerative colitis. *Clin Pharmacokinet* 2019;58(1):15-37.
- [4] Rubin DT, Ananthakrishnan AN, Siegel CA, Sauer BG, Long MD. ACG clinical guideline: ulcerative colitis in adults. *American Journal of Gastroenterology*. 2019;114(3):384-413.
- [5] Ko CW, Singh S, Feuerstein JD, Falck-Ytter C, Falck-Ytter Y, et al. AGA clinical practice guidelines on the management of mild-to-moderate ulcerative colitis. *Gastroenterology* 2019;156:748-764.
- [6] Levesque BG, Loftus EV. Medical management of ulcerative colitis: conventional therapy-azathioprine. *Crohn's Disease and Ulcerative Colitis*. Springer 2017; pp 413-419.
- [7] Nalagatla N, Falloon K, Tran G, Borren NZ, Avalos D, et al. Effect of accelerated infliximab induction on short-and long-term outcomes of acute severe ulcerative colitis: a retrospective multicenter study and meta-analysis. *Clin Gastroenterol Hepatol* 2019;17:502-509.
- [8] Tian C, Huang Y, Wu X, Xu C, Bu H, et al. The efficacy and safety of mesalamine and probiotics in mild-to-moderate ulcerative colitis: a systematic review and meta-analysis. *Evid Based Complement Alternat Med* 2020;2020:6923609.
- [9] Farzaei MH, Bahramsoltani R, Abdolghaffari AH, Sodagari HR, Esfahani SA, et al. A mechanistic review on plant-derived natural compounds as dietary supplements for prevention of inflammatory bowel disease. *Expert Rev Gastroenterol Hepatol* 2016;10:745-758.
- [10] Rahimi R, Nikfar S, Abdollahi M. Induction of clinical response and remission of inflammatory bowel disease by use of herbal medicines: a meta-analysis. *World J Gastroenterol* 2013;19:5738-5749.
- [11] Al-Mouhajer L, Chabo R, Saab AM, Saade K, Makhlof H. Antibacterial activities of essential oils isolated from two species *Cupressus arizonica* Greene and *Cupressus sempervirens* L.(Var. horizontal and pyramidalis). *Eur J Biomed Pharm Sci*. 2017;4:430-435.
- [12] Khouaja W, Oliveira R, Raïes A, Dias ACP. Antifungal activity of the essential oils from *Cupressus arizonica* var. *arizonica* and var. *glabra*. *Ind Crops Prod* 2015;77:614-623.
- [13] Sedaghat MM, Dehkordi AS, Khanavi M, Abai MR, Mohtarami F, et al. Chemical composition and larvicidal activity of essential oil of *Cupressus arizonica* EL Greene against malaria vector *Anopheles stephensi* Liston (Diptera: Culicidae). *Pharmacogn Res* 2011;3:135-139.
- [14] Emami SA, Fakhrjafary M, Tafaghodi M, Hassanzadeh MK. Chemical composition and antioxidant activities of the essential oils of different parts of *cupressus arizonica* greene. *J Essent Oil Res* 2010;22:193-199.
- [15] Al-Sayed E, Gad HA, El-Shazly M, Abdel-Daim MM, Nasser Singab A. Anti-inflammatory and analgesic activities of cupressufflavone from *Cupressus macrocarpa*: Impact on pro-inflammatory mediators. *Drug Dev Res* 2018;79:22-28.

- [16] Emami SA, Shahani A, Khayyat MH. Antioxidant activity of leaves and fruits of cultivated conifers in Iran. *Jundishapur J Nat Pharm Prod* 2013;8:113-117.
- [17] Al-Sayed E, Ke T-Y, Hwang T-L, Chen S-R, Korinek M, et al. Cytotoxic and anti-inflammatory effects of lignans and diterpenes from *Cupressus macrocarpa*. *Bioorg Med Chem Lett* 2020;30:127127.
- [18] Lopéz L, Villavicencio M, Albores A, Martínez M, De la Garza J, et al. *Cupressus lusitanica* (Cupressaceae) leaf extract induces apoptosis in cancer cells. *J Ethnopharmacol* 2002;80:115-120.
- [19] Sadeghi-Aliabadi H, Emami SA, Saeidi M, Jafarian A. Cytotoxic effects of the extracts of Iranian *Taxus baccata* and *Cupressus horizontalis* on cancer cells. *Iran J Pharm Res* 2003;2:107-110.
- [20] Zhang J, Rahman AA, Jain S, Jacob MR, Khan SI, et al. Antimicrobial and antiparasitic abietane diterpenoids from *Cupressus sempervirens*. *Res Rep Med Chem* 2012;2:1-6.
- [21] Koriem KM, Gad IB, Nasiry ZK. Protective effect of *Cupressus sempervirens* extract against indomethacin-induced gastric ulcer in rats. *Interdiscip Toxicol* 2015;8:25-34.
- [22] Sepehrimanesh M, Samimi N, Koohi-Hosseinabadi O, Mokhtari M, Amiri-Zadeh, et al. Effects of *Cupressus sempervirens* extract on the healing of acetic acid-induced ulcerative colitis in rat. *J Coloproctology* 2018;38:309-313.
- [23] Chéraif I, Jannet HB, Hammami M, Khouja M, Mighri Z. Chemical composition and antimicrobial activity of essential oils of *Cupressus arizonica* Greene. *Biochem Syst Ecology* 2007;35:813-820.
- [24] Magalhães R, Torres D, Cavalcante R, Mota F, Moreira H, et al. Gastroprotective effect of alpha-pinene and its correlation with antiulcerogenic activity of essential oils obtained from *Hyptis* species. *Pharmacogn Mag* 2015;11:123-130.
- [25] Memariani Z, Sharifzadeh M, Bozorgi M, Hajimahmoodi M, Farzaei MH, et al. Protective effect of essential oil of *Pistacia atlantica* Desf. on peptic ulcer: role of α -pinene. *J Tradit Chin Med* 2017;37:57-63.
- [26] Minaiyan M, Karimi F, Ghannadi A. Anti-inflammatory effect of *Pistacia atlantica* subsp. *kurdica* volatile oil and gum on acetic acid-induced acute colitis in rat. *Res J Pharmacogn* 2015;2:1-12.
- [27] Al-Sayed E, Gad HA, El-Shazly M, Abdel-Daim MM, Nasser Singab A. Anti-inflammatory and analgesic activities of cupressuflavone from *Cupressus macrocarpa*: Impact on pro-inflammatory mediators. *Drug Dev Res* 2018;79:22-28.
- [28] Samimi N, Farjam M. The effect of *Cupressus sempervirens* on ulcerative colitis: do pathological changes improve by oxidative stress amelioration? *Galen Med J* 2019;8:e1650.
- [29] Fakhri S, Jafarian S, Majnooni MB, Farzaei MH, Mohammadi-Noori E, et al. Anti-nociceptive and anti-inflammatory activities of the essential oil isolated from *Cupressus arizonica* Greene fruits. *Korean J Pain* 2022;35:33-42.
- [30] Harborne A. *Phytochemical Methods a Guide to Modern Techniques of Plant Analysis*: Springer Science & Business Media 1998.
- [31] Talebi M, Zarshenas MM, Yazdani E, Moein M. Preparation and evaluation of possible antioxidant activities of rose traditional tablet“(qurs-e-ward)” a selected traditional persian medicine (tpm) formulation via various procedures. *Curr Drug Discov Technol* 2021;18:e28092020186381.
- [32] Yazdani E, Talebi M, Zarshenas M, Moein M. Evaluation of possible antioxidant activities of barberry solid formulation, a selected formulation from Traditional Persian Medicine (TPM) via various procedures. *Biointerface Res Appl Chem* 2019;9:4517-4521.
- [33] Okayasu I, Hatakeyama S, Yamada M, Ohkusa T, Inagaki Y, et al. A novel method in the induction of reliable experimental acute and chronic ulcerative colitis in mice. *Gastroenterology* 1990;98:694-702.
- [34] Goyal N, Rana A, Ahlawat A, Bijjem KRV, Kumar P. Animal models of inflammatory bowel disease: a review. *Inflammopharmacology* 2014;22:219-233.
- [35] Somani SJ, Modi KP, Majumdar AS, Sadarani BN. Phytochemicals and their potential usefulness in inflammatory bowel disease. *Phytother Res* 2015;29:339-350.
- [36] Farzaei MH, Ghasemi-Niri SF, Abdolghafari AH, Baeeri M, Khanavi M, et al. Biochemical and histopathological evidence on the beneficial effects of *Tragopogon graminifolius* in TNBS-induced colitis. *Pharm Biol* 2015;53:429-436.
- [37] Patil MVK, Kandhare AD, Bhise SD. Effect of aqueous extract of *Cucumis sativus* Linn. fruit in ulcerative colitis in laboratory animals. *Asian Pac J Trop Biomed* 2012;2:S962-S969.
- [38] Kandhare AD, Raygude KS, Ghosh P, Ghule AE, Gosavi TP, et al. Effect of hydroalcoholic extract of *Hibiscus rosa sinensis* Linn. leaves in experimental colitis in rats. *Asian Pac J Trop Biomed* 2012;2:337-344.
- [39] El-Abhar HS, Hammad LN, Gawad HSA. Modulating effect of ginger extract on rats with ulcerative colitis. *J Ethnopharmacol* 2008;118:367-372.
- [40] Dundar E, Olgun EG, Isiksoy S, Kurkcuoglu M, Baser KHC, et al. The effects of intra-rectal and intra-peritoneal application of *Origanum onites* L. essential oil on 2, 4, 6-trinitrobenzenesulfonic acid-induced colitis in the rat. *Exp Toxicol Pathol* 2008;59:399-408.
- [41] Rezayat SM, Dehpour AR, Motamed SM, Yazdanparast M, Chamanara M, et al. *Foeniculum vulgare* essential oil ameliorates acetic acid-induced colitis in rats through the inhibition of NF- κ B pathway. *Inflammopharmacology* 2018;26:851-859.
- [42] Rashidian A, Akbarzadeh D, Asgarpanah J, Dehpour A. *Bunium persicum* essential oil reduced acetic acid-induced rat colitis through suppression of NF- κ B pathway. *Avicenna J Phytomed* 2021;11:505-514.
- [43] Jedidi S, Sammari H, Selmi H, Hosni K, Rtibi K, et al. Strong protective effects of *Salvia officinalis* L. leaves decoction extract against acetic acid-induced ulcerative colitis and metabolic disorders in rat. *J Funct Foods* 2021;79:104406.
- [44] El-Abhar HS, Hammad LNA, Gawad HSA. Modulating effect of ginger extract on rats with ulcerative colitis. *J Ethnopharmacol* 2008;118:367-372.
- [45] Rogler G, Andus T. Cytokines in Inflammatory bowel disease. *World J Surg* 1998;22:382-389.
- [46] Gautam MK, Goel S, Ghatule RR, Singh A, Nath G, et al.

- Curative effect of Terminalia chebula extract on acetic acid-induced experimental colitis: role of antioxidants, free radicals and acute inflammatory marker. *Inflammopharmacology* 2013;21:377-383.
- [47] Keshavarz A, Minaiyan M, Ghannadi A, Mahzouni P. Effects of *Carum carvi* L. (Caraway) extract and essential oil on TNBS-induced colitis in rats. *Res Pharm Sci* 2013;8:1-8.
- [48] Vezza T, Rodríguez-Nogales A, Algieri F, Utrilla MP, Rodríguez-Cabezas ME, et al. Flavonoids in inflammatory bowel disease: a review. *Nutrients*. 2016;8(4):211.
- [49] Kim D-S, Lee H-J, Jeon Y-D, Han Y-H, Kee J-Y, et al. Alpha-pinene exhibits anti-inflammatory activity through the suppression of MAPKs and the NF- κ B pathway in mouse peritoneal macrophages. *Am J Chin Med* 2015;43:731-742.
- [50] Su Y-C, Hsu K-P, Hua K-F, Ho C-L. Composition, in vitro anti-inflammatory, antioxidant and antimicrobial activities of essential oils from leaf and twig parts of *Cupressus cashmeriana*. *Nat Prod Commun* 2015;10:1461-1464.
- [51] Tumen I, Süntar I, Keleş H, Küpeli Akkol E. A therapeutic approach for wound healing by using essential oils of *Cupressus* and *Juniperus* species growing in turkey. *Evid Based Complement Alternat Med* 2012;728281.
- [52] Farzaei MH, Rahimi R, Abdollahi M. The role of dietary polyphenols in the management of inflammatory bowel disease. *Curr Pharm Biotech* 2015;16:196-210.
- [53] Alabi QK, Akomolafe RO, Omole JG, Adefisayo MA, Ogundipe OL, et al. Polyphenol-rich extract of *Ocimum gratissimum* leaves ameliorates colitis via attenuating colonic mucosa injury and regulating pro-inflammatory cytokines production and oxidative stress. *Biomed Pharmacother* 2018;103:812-822.
- [54] Khodayar B, Farzaei MH, Abdolghaffari AH, Bahramsoltani R, Baeeri M, et al. The protective effect of the gallic acid against TNBS-induced ulcerative colitis in rats: role of inflammatory parameters. *J Iran Med Council* 2018;1:34-42.
- [55] Kim T, Song B, Cho KS, Lee I-S. Therapeutic potential of volatile terpenes and terpenoids from forests for inflammatory diseases. *Int J Mol Sci* 2020;21:2187.
- [56] Passos FRS, Araújo-Filho HG, Monteiro BS, Shanmugam S, Araújo AAdS, et al. Anti-inflammatory and modulatory effects of steroidal saponins and sapogenins on cytokines: A review of pre-clinical research. *Phytomedicine* 2022;96:153842.
- [57] Liu Y, Zhou M, Yang M, Jin C, Song Y, et al. Pulsatilla chinensis saponins ameliorate inflammation and dss-induced ulcerative colitis in rats by regulating the composition and diversity of intestinal flora. *Front Cell Infect Microbiol* 2021;11:728929.
- [58] Lu Q-G, Zeng L, Li X-H, Liu Y, Du X-F, et al. Protective effects of panax notoginseng saponin on dextran sulfate sodium-induced colitis in rats through phosphoinositide-3-kinase protein kinase B signaling pathway inhibition. *World J Gastroenterol* 2020;26:1156-1171.
- [59] Guo H, Wan B, Wang J, Zhang J, Yao W, et al. Astragalus saponins inhibit cell growth, aerobic glycolysis and attenuate the inflammatory response in a DSS-induced colitis model. *Int J Mol Med* 2019;43:1041-1048.
- [60] Afsharypuor S, Tavakoli P. Essential oil constituents of leaves and fruits of *Cupressus arizonica* Greene. *J Essent Oil Res* 2005;17:225-226.
- [61] Minaiyan M, Ghannadi A, Afsharipour M, Mahzouni P. Effects of extract and essential oil of *Rosmarinus officinalis* L. on TNBS-induced colitis in rats. *Res Pharm Sci* 2011;6:13-21