



Antioxidant and Protective Effect of *Ajuga chamaecistus* ssp. *tomentella* on CCl₄-Induced Liver Toxicity in Rat

Maryam Heydari^{1,2,3}, Mahdi Vazirian⁴, Seyede Nargess Sadati Lamardi⁵,
Niloofar Nazari⁵, Omid Sabzevari^{2,3*}

¹Faculty of Pharmacy, International Campus, Tehran University of Medical Sciences, Tehran, Iran

²Department of Toxicology and Pharmacology, School of Pharmacy, Tehran University of Medical Sciences, Tehran, Iran

³Toxicology and Poisoning Centre, Tehran University of Medical Sciences, Tehran, Iran

⁴Department of Pharmacognosy, School of Pharmacy, Tehran University of Medical Sciences, Tehran, Iran

⁵Department of Traditional Pharmacy, School of Persian Medicine, Tehran University of Medical Sciences, Tehran, Iran

Received: 10 Aug 2024

Revised: 15 Dec 2024

Accepted: 29 Dec 2024

Abstract

Ajuga chamaecistus ssp. *tomentella* (known as “komafitoos”) has been used in traditional Persian medicine for treating various illnesses including liver ailments. This study aims to evaluate the antioxidant and hepatoprotective effect of *A. chamaecistus* ssp. *tomentella*. Chloroform, ethyl acetate (EAF), and the remaining hydroalcoholic fractions were separated from the total extract of the aerial parts of the plant and their antioxidant activity was evaluated using radical scavenging assay method (2,2-diphenyl-1-picrylhydrazyl, DPPH). The EAF was assessed against carbon tetrachloride (CCl₄)-induced toxicity in rats. Rats were parted into 7 groups each containing 6 animals: sham (normal saline), CCl₄ (single dose of 1 mL/kg b.w., i.p.), treatment groups 3, 4, 5 (treated 7 days with 25, 50 or 100 mg/kg EAF, respectively, p.o.) and 6 (treated 7 days with 100 mg/kg silymarin, p.o.) following a single dose of 1 mL/kg CCl₄, i.p.). Group 7 received 100 mg/kg ethyl acetate fraction for 7 days. Animals were sacrificed 24 h after the last dose and total protein content and biochemical parameters were assayed in the serum. Glutathione, malondialdehyde, and superoxide dismutase levels were measured in the liver homogenates. Histological changes in the liver tissue were examined using a light microscope. EAF showed the best antioxidant activity according to the DPPH free radical scavenging assay (IC₅₀=60.5 µg/mL) in comparison to the other fractions. It significantly alleviated serum transaminase levels, alkaline phosphatase, alanine transaminase, aspartate aminotransferase, and lactate dehydrogenase, especially with 25 and 50 mg/kg doses. Treatment with EAF increased superoxide dismutase activity and glutathione content; while decreasing the malondialdehyde level similar to the Silymarin group. Histological examination further confirmed our biochemical findings. *A. chamaecistus* ssp. *tomentella* showed acceptable hepatoprotective activity, as described by traditional Persian medicine.

Keywords: *Ajuga chamaecistus* ssp. *Tomentella*; Antioxidant; CCl₄; Hepatoprotective effect

doi <http://doi.org/10.18502/tim.v10i2.19058>

Citation: Heydari M, Vazirian M, Sadati Lamardi SN, Nazari N, Sabzevari O. Antioxidant and Protective Effect of *Ajuga chamaecistus* ssp. *tomentella* on CCl₄-Induced Liver Toxicity in Rat. Trad Integr Med 2025;10(2):130-137. <http://doi.org/10.18502/tim.v10i2.19058>

*Corresponding Author: Omid Sabzevari

Department of Toxicology and Pharmacology, School of Pharmacy, Tehran University of Medical Sciences, Tehran, Iran

Email: omid@tums.ac.ir

Copyright © 2025 Tehran University of Medical Sciences. Published by Tehran University of Medical Sciences. This work is licensed under a Creative Commons Attribution-NonCommercial 4.0 International license (<https://creativecommons.org/licenses/by-nc/4.0/>). Noncommercial uses of the work are permitted, provided the original work is properly cited.



Introduction

Liver is one of the most essential body organs, which has a fundamental role in adjusting diverse physiological processes. It has a role in several vital functions including the metabolism of carbohydrates and fats, bile secretion, and storage of vitamins, while detoxifies exogenous and endogenous substances in the body, as well as producing useful agents. Hepatic disorders are due to damage to cells, tissues, organ structure, or function which could result from biological agents such as bacteria, viruses, and parasites, and autoimmune illnesses in addition to certain medications, and toxic compounds like carbon tetrachloride (CCl₄). Liver damage by CCl₄ is a laboratory model widely used to investigate mechanisms of cellular damage caused by oxidative injury. It is also used to evaluate the useful therapeutic application of antioxidants and drugs [1,2].

Despite the enormous advances in modern medicine, there is no remedy to completely restore liver function, or help hepatocytes regeneration. In recent years, medicinal plants and natural compounds have received great attention due to their diverse medicinal properties, such as hepatoprotective and antioxidant activities. Interest in studying natural compounds such as flavonoids, terpenoids, and steroids is increased for their potential antioxidant activity in eliminating free radicals that can protect humans against degenerative diseases. Many herbs are widely used to recover liver from various complications [2-5].

The common name of the genus *Ajuga* (Lamiaceae) is Bugle, and there are five species of this genus in Iran, amongst which *A. chamaecistus* ssp. *tomentella* is an endemic one [6]. In traditional Persian medicine, the genus *Ajuga* [*Kamaphytus*] has been used for the treatment of disorders such as joint pain, jaundice, gout, sciatica, amenorrhea, and wounds [7]. Several pharmacologic and ethnobotanic reports have emphasized the traditional use of various species of this genus including anti-inflammatory, hypolipidemic, hypoglycemic, analgesic, antioxidant, anabolic, anti-arthritis, hepatoprotective, antipyretic, cardiogenic, anthelmintic, anti-malaria, antibacterial and antifungal properties [8-13]. Several phytochemicals have been isolated from *Ajuga* species comprising phytoecdysteroids [14,15], neo-clerodane-diterpenes [16,17], flavonoids, iridoids, [18], phenylethyl glycoside, withanolides [19,20], and essential oils [21].

The purpose of this study was to evaluate the antioxidant activity and hepatoprotective effect of *Ajuga chamaecistus* ssp. *tomentella*.

Materials and Methods

The plant material

Ajuga chamaecistus Ging. ssp. *tomentella* (Boiss.)

Rech. f. aerial parts were collected from east of Tehran, Iran, in June 2014, dried in proper condition then verified by Prof. G. Amin. A voucher specimen (TEH-6697) was placed in the herbarium of the Department of Pharmacognosy, Faculty of Pharmacy, Tehran University of Medical Sciences, Tehran, Iran.

Hydroalcoholic extraction

The well-dried and grounded aerial parts of *A. chamaecistus* ssp. *tomentella* (195 g) was extracted with 80% ethanol three times at room temperature. After evaporation of the solvent on a rotary evaporator (Heidolph, Model: Hei-VAP Value Hand Lift; Germany) and a vacuum oven (SHEL LAB, Sweden), a dark brown extract was obtained (42 g).

Fractionation of total extract

The extract (32 g) was suspended in 200 mL of 80% ethanol using an ultrasonic machine (Hielscher, Germany) and partitioned between hydroalcoholic, chloroform, and ethyl acetate. Removal of the solvents with a rotary evaporator resulted in production of chloroform, ethyl acetate, and residual hydroalcoholic fractions.

Free radical scavenging activity

The 2,2-diphenyl-1-picrylhydrazyl (DPPH) assay was done based on the method of Brand-Williams et al. with some modifications [22,23]. The total extract along with chloroform, ethyl acetate, and aqueous-ethanol fractions were tested at concentrations of 25, 50, and 100 µg/mL, dissolved in methanol. Each sample (1 mL) was combined with a fresh methanolic solution of 40 µg/mL DPPH. After 30 minutes of incubation in the dark at room temperature, absorbance was measured at 517 nm against a blank. The percentage of inhibition was calculated using the equation:

$$I = [(A_{\text{blank}} - A_{\text{sample}}) / A_{\text{blank}}] \times 100$$

where A_{blank} is the absorbance of the control (DPPH solution without the sample). The IC₅₀ value (the concentration of samples showing 50% scavenging activity) was calculated based on sample concentration against the percentage of inhibition and reported as mean ± standard deviation.

Animals

Male albino Wistar rats weighing 250±30 g were obtained from the Faculty of Pharmacy, Tehran University of Medical Sciences, and divided into groups of 6 with a 12 h light-dark cycle and constant temperature (22°C). Animals were allowed to adapt to the laboratory for 30 min before the tests began. All of the animal experimental procedures were undertaken in compliance with the NIH Guide for the Care and Use of Laboratory Animals (National Institutes of Health Publication No. 85-23, revised 1996) and approved by

the Ethical Committee for Animal Experimentation of TUMS (code: IR.TUMS.REC.1395.447). Moreover, thorough efforts were made to minimize the number of animals used and their discomfort.

Drugs and chemicals

Silymarin was purchased from Sigma (chemical St. Louis, MO, The USA); Carbon tetrachloride was purchased from Merck (Germany). The assay ELISA kits were purchased from Zellbio© GmbH (Germany) and Padginteb co, Iran. All other chemicals (ethanol, ethyl acetate, chloroform, acetone, DPPH, formalin, and phosphate buffer) were purchased from Merck (Germany).

Carbon tetrachloride-induced liver damage in rats

Healthy albino rats were divided into 7 groups each containing 6 animals. Group 1 (sham) received normal saline. Group 2 received a single dose of CCl₄ (1 mL/kg body weight, i.p.). Groups 3-6 received CCl₄ (1 mL/kg body weight, i.p.) and were treated 7 days with ethyl acetate fraction at three doses (25, 50, and 100 mg/kg p.o.) or Silymarin (100 mg/kg p.o.), respectively. Group 7 received 100 mg/kg p.o. ethyl acetate fraction. Animals were sacrificed 24 h after the last treatment under Ketamine (100 mg/kg) and Xylazine (16 mg/kg) anesthesia (i.p.).

Biochemical studies

Animals were anesthetized with Ketamine (100 mg/kg) and Xylazine (16 mg/kg) and all blood samples were collected from their hearts through cardiac exsanguination. After clotting at room temperature, the sera were isolated by centrifugation at 2500 rpm for 15 minutes, and stored at -80°C for determination of biochemical parameters including Alanine transaminase (ALT), Aspartate transaminase (AST), Lactate dehydrogenase (LDH) and Alkaline phosphatase (ALP). In addition, liver samples were excised, rinsed in ice-cold normal saline, and stored at -80°C. Antioxidant parameters such as superoxide dismutase (SOD), malondialdehyde (MDA), and glutathione (GSH) were measured spectrophotometrically in liver tissue homogenates [24] using commercially available Zell-

Bio© kits (Germany).

Histopathological examination

Samples taken from the liver were stabled in 10% buffered formalin for 48 hours. Preparation of tissue samples and paraffin blocks was made according to a previous work. Subsequently, tissues with a thickness of 5 µm sectioned by microtome, stained with hematoxylin-eosin and studied using light microscopy [25].

Statistical analysis

The statistical analysis was carried out by One-way Analysis of Variance (ANOVA) using sigma plot version 12.0 and *p* values <0.05 were considered significant.

Results

DPPH radical scavenging activity

The antioxidant activity of total extract, hydroalcoholic, chloroform, and ethyl acetate fractions were evaluated in the present study using DPPH radical scavenging method (Table 1).

The ethyl acetate fraction showed powerful antioxidant activity against DPPH in comparison to other fractions, therefore, lower concentrations of the extract (25 and 50 µg/mL) were employed. Due to spectacular antioxidant activity, the ethyl acetate fraction was chosen for further experimental steps.

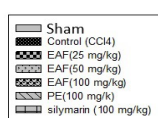
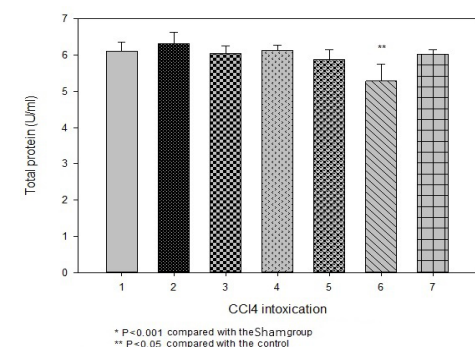
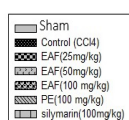
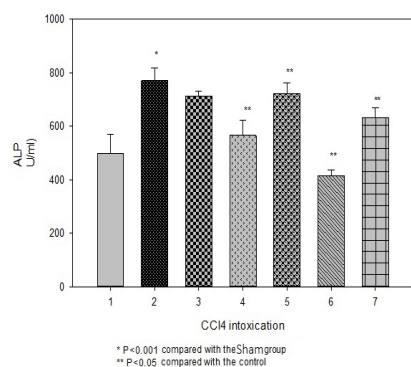
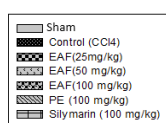
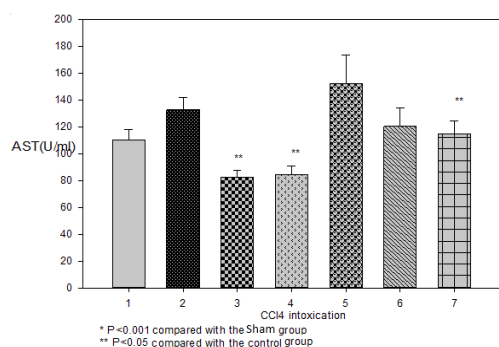
Effect of ethyl acetate fraction (EAF) on serum enzymes AST, ALT, ALP, LDH and total protein

Serum levels of ALT, AST, LDH, ALP, and total protein content are shown in figure 1. Level of serum marker enzymes ALT, AST, ALP, and LDH were significantly increased in CCl₄-administered rats when compared to the sham (*p*<0.05-*p*<0.001). Treatment with EAF at the doses of 50 and 25 mg/kg decreased the serum transaminase levels and LDH. Silymarin (100 mg/kg) was able to lower the elevated levels of ALT and ALP, but not AST and LDH.

Administration of EAF (100 mg/kg) to the healthy rats increased ALT (*p*<0.001) and AST (not significant) levels and decreased ALP (*p*<0.001) and total protein

Table 1. DPPH radical scavenging of total extract and fractions of *Ajuga chamaecistus* ssp. *tomentella* aerial parts

DPPH radical scavenging (%)				
Concentration (µg/ml)	Total extract (TE)	Hydro alcoholic fraction	Chloroform fraction	Ethyl acetate fraction
25	-	-	-	40±2.34
50	-	-	-	70±1.04
100	14.59±1.36	22.97±11.76	43.33±1.92	100±0
500	55.80±10.15	44.09±9.82	69.22±6.08	-
1000	79.53±7.64	70.21±16.09	88.36±11.68	-
IC ₅₀ (µg/ml)	368.72	613.94	150.62	60.5



levels compared to the sham ($p<0.05$).

Effect of EAF on GSH, MDA, and SOD in liver

GSH, MDA, and SOD contents in the homogenized liver of rats are shown in figure 2. GSH was significantly decreased in CCl₄-administered rats. Treatment with all the study groups, except for 50 mg/kg of EAF, restored the level of GSH. There was no significant difference between study groups compared with sham or silymarin groups ($p>0.05$).

MDA was increased significantly in CCl₄-administered rats compared to sham ($p<0.001$). Treatment with all the study groups decreased the increased level of MDA following CCl₄ administration ($p<0.001$). No significant difference was found between EAF treatment groups with sham and silymarin ($p>0.05$).

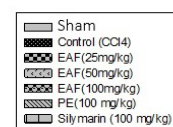
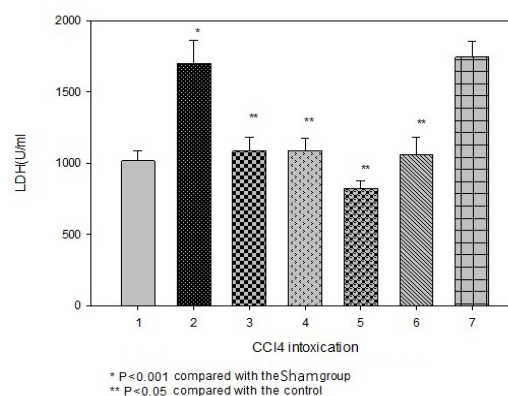
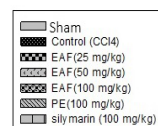
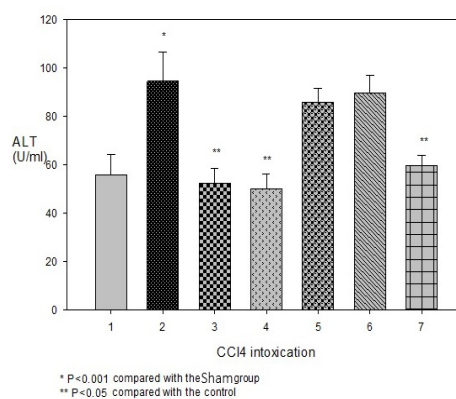


Figure 1. Effect of ethyl acetate fraction (EAF) of *Ajuga chamaecistus* ssp. *tomentella* on serum enzymes AST, ALT, ALP, LDH and total protein.

* Significantly different from the sham group

Significantly different from the CCl₄ group

+ Significantly different from the silymarin group

SOD activity decreased significantly in liver tissue by CCl_4 compared with sham ($p < 0.001$). All treatment groups significantly recovered the SOD levels in comparison to the CCl_4 -administered group ($p < 0.001$) and there was no significant difference between treatment with EAF at the doses of 25 and 50 mg/kg with sham and silymarin groups.

Histopathologic examination

Histopathology results of liver sections are shown in figure 3. In the hepatocytes of CCl_4 -poisoned animals, excessive cell swelling (ballooning degeneration) and core inflation (Karyomegaly), accumulation of fat vacuoles in the cytoplasm, and tubule necrosis were observed. An irregularity in the liver chord structure and sinusoidal vessel obstruction was visible. Extensive bleeding and the presence of mononuclear inflammatory cells (lymphocytes) in some areas, especially in the portal space were observed. In addition, the normal tissue of the liver was replaced by fibrotic tissue (a).

In the silymarin-treated group, cellular inflation was reduced significantly. No traces of blood were observed, liver structure recovered and the symptoms of tissue damage were improved (b).

In the low-dose EAF treatment group (CCl_4 + 25 mg/kg EAF) liver tissue histopathological pattern was similar to the silymarin group in which tissue necrosis and inflammation of the hepatocytes was reduced. However, moderate to severe swelling of hepatocytes was obvious (c). The best hepatoprotective effect was observed following treatment with the moderate dose of EAF (CCl_4 + 50 mg/kg EAF). Liver tissue regeneration is well, though, some hepatocytes with mild cellular inflammation remained (d). The least hepatoprotective effect was observed following treatment with the high dose of EAF (CCl_4 + 100 mg/kg EAF). Severe hyperemia of the central vein and sinusoid vessels was noticeable (e).

No significant histopathological damage was observed following the administration of 50 mg/kg of EAF to healthy animals (f). Administering 100 mg/kg of EAF to healthy animals led to hepatocyte swelling, characterized by an increase in cell volume and a white coloration observable at $\times 200$ magnification, due to fatty mass changes and/or hydropic degeneration in the hepatocyte cells.

Discussion

In our study, we evaluated the antioxidant activity and hepatoprotective effect of *Ajuga chamaecistus* ssp. *tomentella*. The best DPPH free radical scavenging and antioxidant activity was observed from the ethyl acetate fraction ($\text{IC}_{50} = 60.5$) against CCl_4 -induced toxicity in rats. DPPH free radical scavenging is an appropriate method to measure the antioxidant activity.

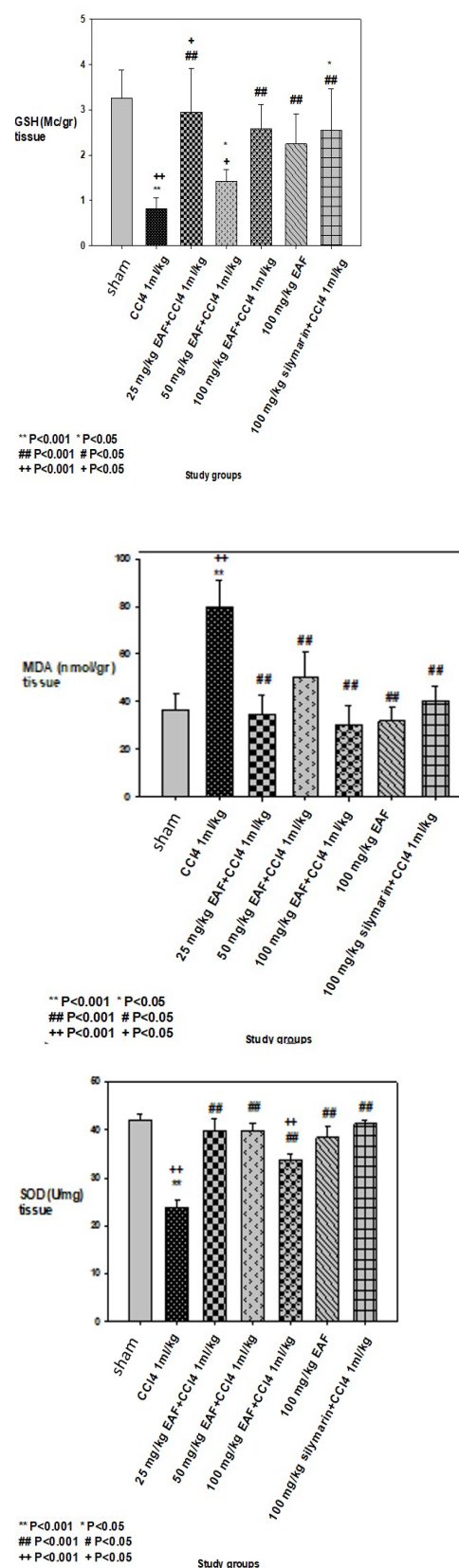


Figure 2. Effect of Ethyl acetate fraction (EAF) of *Ajuga chamaecistus* ssp. *tomentella* on GSH, MDA and SOD levels.

* Significantly different from the sham group

Significantly different from the CCl_4 group

+ Significantly different from the silymarin group

ity of plant extracts. The presence of several tannins, flavonoids, steroids, terpenes, and phytoecdysteroids is reported in *Ajuga* species [26]. Furthermore, phytoecdysteroids and (20-hydroxyecdysone), 2 (Cyasterone), and 3 (8-Acetylharpagide) are present in *Ajuga chamaecistus* ssp. *tomentella* total extract and possess antioxidant and cytotoxic activity by inhibiting free radicals [27,28].

To define the hepatoprotective activity of EAF, rats were intoxicated with CCl_4 (single dose of 1 mL/kg b.w., i.p.), and treated with EAF (25, 50, and 100 mg/kg, p.o.) or silymarin (100 mg/kg, p.o.). CCl_4 is one of the most important hepatotoxins due to its potent oxidative effect on the liver. CCl_4 metabolism by CYP2E1 to the extremely active ROS (CCl_3 radical) plays a significant role in the toxicity. Free radicals attack microsomal lipids which cause peroxidation. They also attach to lipids and micronutrient proteins, leading to activation of secondary biochemical processes.

CCl_4 has been shown to increase ALT, AST, and ALP activities in the plasma that could be considered as an index of injury to the liver parenchymal cells induced by increased levels of AST, ALT, ALP, and LDH activities. Treatment with EAF at doses of 25 and 50 mg/kg decreased the serum transaminase levels similar to silymarin. Administration of EAF at the highest dose (100 mg/kg) to the healthy animals increased ALT and AST values; while lower doses of EAF (25 and 50 mg/kg) and silymarin (100 mg/kg) significantly reduced their concentrations. In a study by Hsieh et al., (2011), it was revealed that *Ajuga bracteosa* extract inhibited the progress of CCl_4 -induced hepatic fibrosis in mice by inhibition of macrophage activation and suppressing liver inflammation. Moreover, *A. bracteosa* protected the liver from damage by reducing the action of plasma aminotransferase (ALT and AST), and improving the histological construction of the liver [8]. All employed EAF doses reduced LDH activity which shows its ability to reduce necrosis and other damage to the liver. Among the treatment groups, EAF (50 mg/kg) was able to reduce ALP which evidenced its effect on biliary tracts. Silymarin treatment did not reduce LDH levels but, was able to reduce ALP levels.

One of the end products in the peroxidation of lipids is MDA, which is produced by chemical damages and reactions that are catalyzed by enzymes from unsaturated fatty acids. The high concentrations of MDA in biological samples are usually considered a pathological condition. Reducing the concentration of oxidative stress biomarkers by various antioxidants or using drugs indicates the beneficial effects of these agents on health [31]. The results of this study showed that MDA was increased significantly in CCl_4 -administered rats compared to sham. Treatment with all the study groups decreased the increased level of MDA

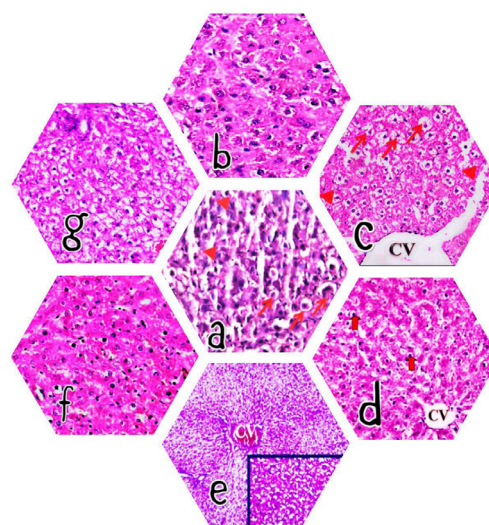


Figure 3. Histological changes in liver of rats exposed to EAF and CCl_4 (x200). **A** CCl_4 -induced section: excessive cell swelling (ballooning degeneration) and core inflation. CV: central vein **B** silymarin treated section (100 mg/kg): cellular inflation reduced significantly and symptoms of tissue damage were improved. **C** Low-dose EAF treatment section (25 mg/kg): tissue necrosis and inflammation of the hepatocytes is reduced, however, moderate to severe swelling of hepatocytes is obvious. **D** Moderate-dose EAF treatment section (50 mg/kg): liver tissue regeneration is well taken place, liver tissue showed mostly normal appearance. **E** High-dose EAF treatment section (100 mg/kg): severe hyperemia of the central vein and sinusoid vessels were noticeable. **F** liver section from control rat received 50 mg/kg of EAF, no significant histopathological damage was observed. **G** liver section from control rat received 100 mg/kg of EAF, resulted hepatocyte swelling and fatty changes.

following CCl_4 administration. All the treatment groups prevented the peroxidation of fatty acids and reduced the oxidative stress in the liver similar to silymarin.

GSH is one of the most plentiful intracellular non-protein thiol molecules in tissues, especially in the liver, which can scavenge free radicals as an antioxidant and prevent the oxidation of proteins by reversible glutathionylation and thus, reduces the damage caused by ROS. GSH also shows a significant role in the detoxification of electrophilic combinations, toxic metals, and microbial proteins. Therefore, GSH plays an essential role in the survival and health of the cells, and the imbalance in GSH levels can lead to various illnesses caused by oxidative stress [32]. In our study, GSH was significantly decreased in CCl_4 -administered rats. Treatment with all the study groups, except for 50 mg/kg of EAF, restored the level of GSH. In addition, a significant difference was observed between Silymarin and EAF at both 25 and 50 mg/kg groups. EAF at the dose of 25 mg/kg, however, had a better effect than Silymarin but the 50 mg/kg EAF was not as effective as Silymarin in restoring GSH. This means that EAF extracts were able to balance the level of GSH in

the liver and protect it against free radicals and peroxides that are the result of the toxicity of CCl_4 . SOD converts superoxide to H_2O_2 and removes it, which is immediately converted to water by glutathione peroxidase (GPx) and CAT. So, the cells protect themselves against the toxic effects of ROS. O_2^- radical, which is superoxide, is converted to O_2 and H_2O_2 by SOD; thus, participating in the enzymatic defense against toxicity among other antioxidant enzymes. [33]. Several studies confirmed that an aqueous extract of *Ajuga iva* and an iridoid compound (8-O-acetyl-harpagide) isolated from this extract increases the antioxidant capacity evidenced by decreasing lipid peroxidation and increasing the antioxidant enzymes (SOD, GSH) activities in plasma, erythrocytes and tissues of diabetic and hypercholesterolemic rats [34-36]. In our study, SOD activity decreased significantly in liver tissue by CCl_4 . All treatment groups significantly recovered the SOD levels to normal, therefore, it can be concluded that the EAF is able to reduce ROS and oxidative stress damage to the liver tissue. There was no significant difference between treatment with EAF at 25 and 50 mg/kg doses and silymarin groups. The results of liver histopathology sections showed that between EAF treatment groups, the dose of 50 mg/kg had a significantly better effect in preventing liver damage and necrosis of hepatocytes, regarding tissue necrosis, and inflammatory cell recruitment rates, as moderate to severe hepatocyte swelling were noticeable in 25 mg/kg groups; while degeneration and necrosis of the liver cells were obvious in the 100 mg/kg group. The higher level of enzymes in the silymarin group than in the lower doses of the extract (25 and 50 mg/kg), and the presence of less extensive liver damage in the 50 mg/kg EAF group, indicate that the 25 and 50 mg/kg doses were more successful than silymarin in reducing enzyme levels; however, there was no statistically significant difference between 25 and 50 mg/kg groups regarding serum enzymes. It seems that healthy cells that still have no degeneration and necrosis are more present in the silymarin group than the lower dose of the extract, and consequently, due to the effect of CCl_4 on healthy cells and the release of intracellular enzymes in the blood, the level of enzymes in the silymarin group is higher than other mentioned groups, despite better histological results. To make a comparative study on histology, according to an article by Wen-Tsong Hsieh and colleagues who studied the hepatoprotective effects of *Ajuga bracteosa* on CCl_4 -induced liver damage, the best effects were observed on the liver tissue in the group treated with the 300 mg/kg of this plant extract. Taken collectively, treatment with EAF can recover the activity of SOD and GSH; while similarly reducing the level of MDA to silymarin. These results in addition to histological examination of the liver samples

established hepatoprotective potential of *A. chamaecistus* ssp. *tomentella*.

In a study conducted by Sadati et al., the acute and chronic toxicity of the plant's hydroalcoholic extract was evaluated in rats. The acute toxicity test indicated that the ethanolic extract was safe at doses up to 6,000 mg/kg. In the sub-chronic toxicity study, administering the extract at 1,000 mg/kg for 23 and 45 days significantly reduced cholesterol and triglyceride levels. Histopathological analysis revealed no notable differences in tissue samples between treated and control groups after 23 and 45 days [37]. It appears that if the EAF doses used in our study were converted to clinical doses, they would still be within a non-toxic and usable range except for 100 mg/kg where improvement in serum enzyme levels and histological manifestations at this dose was also not adequate in our study.

So, although working with laboratory animals, conducting laboratory tests, and even collecting plants can be considered challenges and limitations of the study, all these steps were carried out with the enthusiasm of achieving a fascinating result. Based on that, it is recommended that appropriate clinical studies be designed for this plant, which could open a new chapter in the treatment of many liver diseases in modern medicine.

Conclusion

It appears that *A. chamaecistus* ssp. *tomentella* demonstrates a commendable potential for liver protection, aligning with the descriptions in traditional Persian medicine.

Funding

This publication and work is based on studies sponsored and funded by the Vice Chancellor for Research (Project No. 31789), Tehran University of Medical Sciences, Tehran, Iran.

Conflict of Interests

The authors declare that there are no conflicts of interest and have read and understood the Conflict-of-Interest Policy from the Journal.

Acknowledgments

None.

References

- [1] Basu S. Carbon tetrachloride-induced lipid peroxidation: eicosanoid formation and their regulation by antioxidant nutrients. *Toxicology* 2003;189:113-127.
- [2] Madrigal-Santillan E, Madrigal-Bujaidar E, Alvarez-Gonzalez I, Sumaya-Martinez MT, Gutierrez-Salinas J, et al. Review of natural products with hepatoprotective effects. *World J Gastro-*

- enterol 2014;20:14787-14804.
- [3] Eidi A, Moghadam JZ, Mortazavi P, Rezazadeh S, Olamafar S. Hepatoprotective effects of *Juglans regia* extract against CCl₄-induced oxidative damage in rats. *Pharm Biol* 2013;51:558-565.
 - [4] DeFeudis FV, Papadopoulos V, Drieu K. Ginkgo biloba extracts and cancer: a research area in its infancy. *Fundam Clin Pharmacol* 2003;17:405-417.
 - [5] Banskota AH, Tezuka Y, Adnyana IK, Xiong Q, Hase K, et al. Hepatoprotective effect of *Combretum quadrangulare* and its constituents. *Biol Pharm Bull* 2000;23:456-460.
 - [6] Mozaffarian V. A dictionary of Iranian Plant Names. Tehran: Farhangmoaser 2007.
 - [7] Tonkaboni M, In: Rahimi R, Shams-ardekani M, Farjadmand F. *Tohfeh-al-Momenin*. Tehran, Iran: Shahid Beheshti University of Medical Sciences 2007.
 - [8] Hsieh WT, Liu YT, Lin WC. Anti-inflammatory properties of *Ajuga bracteosa* in vivo and in vitro study and their effects on mouse model of liver fibrosis. *J Ethnopharmacol* 2011;135:116-125.
 - [9] Gautam R, Jachak SM, Saklani A. Anti-inflammatory effect of *Ajuga bracteosa* Wall Ex Benth. mediated through cyclooxygenase (COX) inhibition. *J Ethnopharmacol* 2011;133:928-930.
 - [10] El-Hilaly J, Tahraoui A, Israili ZH, Lyoussi B. Acute hypoglycemic, hypocholesterolemic and hypotriglyceridemic effects of continuous intravenous infusion of a lyophilised aqueous extract of *Ajuga iva* L. Schreber whole plant in streptozotocin-induced diabetic rats. *Pak J Pharm Sci* 2007;20:261-268.
 - [11] El Hilaly J, Lyoussi B. Hypoglycaemic effect of the lyophilised aqueous extract of *Ajuga iva* in normal and streptozotocin diabetic rats. *J Ethnopharmacol* 2002;80:109-113.
 - [12] Ono Y, Fukaya Y, Imai S, Yamakuni T. Beneficial effects of *Ajuga decumbens* on osteoporosis and arthritis. *Biol Pharm Bull* 2008;31:1199-1204.
 - [13] Kuria KA, Chepkwony H, Govaerts C, Roets E, Busson R, et al. The antiplasmodial activity of isolates from *Ajuga remota*. *J Nat Prod* 2002;65:789-793.
 - [14] Castro A, Coll J, Tandron YA, Pant AK, Mathela CS. Phytoecdysteroids from *Ajuga macrosperma* var. *breviflora* roots. *J Nat Prod* 2008;71:1294-1296.
 - [15] Vanyolos A, Simon A, Toth G, Polgar L, Kele Z, et al. C-29 ecdysteroids from *Ajuga reptans* var. *reptans*. *J Nat Prod* 2009;72:929-932.
 - [16] Castro A, Coll J, Pant AK, Pakrash O. Neo-clerodane diterpenoids from *Ajuga macrosperma* var. *breviflora*. *Nat Prod Commun* 2015;10:857-860.
 - [17] Castro A, Coll J, Arfan M. Neo-clerodane diterpenoids from *Ajuga bracteosa*. *J Nat Prod* 2011;74:1036-1041.
 - [18] Manguro LO, Ogur JA, Okora DM, Wagai SO, Lemmen P. Further flavonol and iridoid glycosides from *Ajuga remota* aerial parts. *J Asian Nat Prod Res* 2007;9:617-629.
 - [19] Akbay P, Calis I, Heilmann J, Sticher O. New stigmastane sterols from *Ajuga salicifolia*. *J Nat Prod* 2003;66:461-465.
 - [20] Akbay P, Calis I, Heilmann J, Sticher O. Ionone, iridoid and phenylethanoid glycosides from *Ajuga salicifolia*. *Z Naturforsch C* 2003;58:177-180.
 - [21] Ardekani MRS, Khanavi M, Taheri P, Samadi N, Safaripour E, et al. The essential oil composition of *Ajuga chamaecistus* Ging. subsp. *Tomentella* Rech. f. *J Essent Oil-Bear Plants* 2010;13:45-51.
 - [22] Brand-Williams W, Cuvelier M-E, Berset C. Use of a free radical method to evaluate antioxidant activity. *LWT-Food Sci Technol* 1995;28:25-30.
 - [23] Kahkeshani N, Farahanikia B, Mahdavian P, Abdolghaffari A, Hassanzadeh G, et al. Antioxidant and burn healing potential of *Galium odoratum* extracts. *Res Pharm Sci* 2013;8:197-203.
 - [24] Sepand MR, Razavi-Azarkhiavi K, Omid A, Zirak MR, Sabzevari S, et al. Effect of acetyl-L-carnitine on antioxidant status, lipid peroxidation, and oxidative damage of arsenic in rat. *Biol Trace Element Res* 2016;171:107-115.
 - [25] Minaie B. Basic principles and methods of histology and stereology. Tehran University Press. Tehran 2001; pp 15-25.
 - [26] Ramazanov NS. Phytoecdysteroids and other biologically active compounds from plants of the Genus *Ajuga*. *Chem Nat Compd* 2005;41:361-369.
 - [27] Cai YJ, Dai JQ, Fang JG, Ma LP, Hou LF, et al. Antioxidative and free radical scavenging effects of ecdysteroids from *Serratula stragulata*. *Can J Physiol Pharmacol* 2002;80:1187-1194.
 - [28] Hu J, Luo CX, Chu WH, Shan YA, Qian ZM, et al. 20-Hydroxyecdysone protects against oxidative stress-induced neuronal injury by scavenging free radicals and modulating NF-kappaB and JNK pathways. *PLoS One* 2012;7:e50764.
 - [29] Surai PF. Silymarin as a natural antioxidant: an overview of the current evidence and perspectives. *Antioxidants* 2015;4:204-247.
 - [30] Lim HK, Kim HS, Choi HS, Choi J, Kim SH, et al. Effects of bergenin, the major constituent of *Mallotus japonicus* against D-galactosamine-induced hepatotoxicity in rats. *Pharmacology* 2001;63:71-75.
 - [31] Tsikas D. Assessment of lipid peroxidation by measuring malondialdehyde (MDA) and relatives in biological samples: Analytical and biological challenges. *Anal Biochem* 2017;524:13-30.
 - [32] Zhao H, Ruan H, Li H. Progress in the research of GSH in cells. *Chin Sci Bull* 2011;56:3057-3063.
 - [33] Halliwell B. Free radicals, antioxidants, and human disease: curiosity, cause, or consequence? *The Lancet* 1994;344:721-724.
 - [34] Bouderbala S, Lamri-Senhadji M, Prost J, Lacaille-Dubois MA, Bouchenak M. Changes in antioxidant defense status in hypercholesterolemic rats treated with *Ajuga iva*. *Phytomedicine* 2008;15:453-461.
 - [35] Taleb-Senouci D, Ghomari H, Krouf D, Bouderbala S, Prost J, et al. Antioxidant effect of *Ajuga iva* aqueous extract in streptozotocin-induced diabetic rats. *Phytomedicine* 2009;16:623-631.
 - [36] Bouderbala S, Prost J, Lacaille-Dubois MA, Bouchenak M. Iridoid extracts from *Ajuga iva* increase the antioxidant enzyme activities in red blood cells of rats fed a cholesterol-rich diet. *Nutr Res* 2010;30:358-365.
 - [37] Rahiminiya A, Herizchi Ghadim H, Sadati Lamardi SN. Medicinal importance of *ajuga* species in iran: ethnobotanical and traditional applications, phytochemical, and pharmacological studies. *Jundishapur J Nat Pharm Prod* 2022;17:e119209.